UNKNOWN DEAD NEONATE– MATERNAL NEONATICIDE? A CASE REPORT

Mary Sowjanya G[1] Surender Reddy [2]
[1] Department of Forensic Medicine, KAMSRC, Hyderabad, Telangana, India.
[2] Department of Forensic Medicine, GMC/GGH, Mancherial, Telangana, India.

Corresponding Author Dr. G Mary Sowjanya
Email: sowjanya.gaddala@gmail.com | Mobile: 83749 09757
Received: May 11, 2024; Accepted: January 11, 2025

ABSTRACT

Neonaticide refers to the killing of a newborn within 24 hours of birth, often distinguished by unique diagnostic and motivational factors compared to other forms of homicide. This act, which is typically committed by the mother, is a cognizable offense, though definitions and legal interpretations may vary by country. Predicting the risk of neonaticide is complex, as there is no single indicative factor and various contributing elements may be involved.

This case report details the killing of a female newborn by her mother following a clandestine and unassisted birth in a secluded area of rural Telangana. Autopsy findings indicated manual strangulation. The report underscores the medico-legal implications of such cases. The role of the autopsy surgeon is crucial in determining if the victim was born alive, ascertaining the cause of death, and collecting samples for maternal identification. A thorough investigation of potential neonaticide necessitates methodical radiological (when available), external, and internal examinations by the autopsy surgeon.

Keywords: Neonaticide, MaternalFilicide,Medico Legal Autopsy

INTRODUCTION

Neonaticide, a crime almost always perpetrated by the biological mother, occurs throughout the world and appears to be one of the least avoidable crimes.1-3 Itis defined as an act of killing a newborn, immediately or within 24 hours, because the child is not wanted.4,5The killing of a newborn differs from other forms of homicide in terms of diagnosis and motives.6 Neonaticide can be either an actof commission (e.g., strangulation, smothering,poisoning) or an act of omission (e.g., failure to protectfrom heat or cold, with holding breast feeding). 7 We presenta case of a female newborn discovered dead ina secluded location by sanitation workers in rural Telangana high lighting the importance of autopsy and medicolegal implications in such cases.

Case Report

As per the police inquest,an unknown deadfemale fetus was found in outskirtsof rural Telangana at around 2: 00pm.At the scene of crime,the body was found in prone position naked with the right lower limb and the lower third of the left leg missing and gnawed by animals.

During the autopsy, the body of a female baby was found soiled with mud and grass particles, wrapped in a multicolored cloth and a blue towel. The right lower limb and the lower third of the left lower limb were absent. There were post-mortem ant-bite marks in multiple areas. The body measured 55 cm in length and weighed 1.52 kg, with a head circumference of 32 cm, chest circumference of 34 cm, and abdominal circumference of 32 cm. The baby had black scalp hair measuring 4 cm, and the umbilical cord was severed with irregular margins at the cut end, not clamped, and measured 4 cm in length. The fingernails extended beyond the

fingertips. The left eye was bulging out.

Post-mortem lividity was observed on the back of the body, and there was greenish discoloration with skin blistering and peeling.

Antemortem injuries included external contusions measuring 5x4 cm and 4x2 cm on the front of the right and left upper neck just below the angle of the mandible. Multiple imprint abrasions of varying dimensions (1.5-2 cm x 0.5-1 cm) were present in an area of 12x8 cm on the back of the left side of the chest.

Internal injuries included a contusion of 2x1 cm on the front of the right upper part of the thyrohyoid and a 2.5x1 cm contusion on the anterior aspect of the left upper part of the sternocleidomastoid muscle. There was also a 1x1 cm contusion on the left thyrohyoid muscles.Ossification centers of both feet were not identifiable due to the absence of the limbs. Thesternum ossification centers were observed.

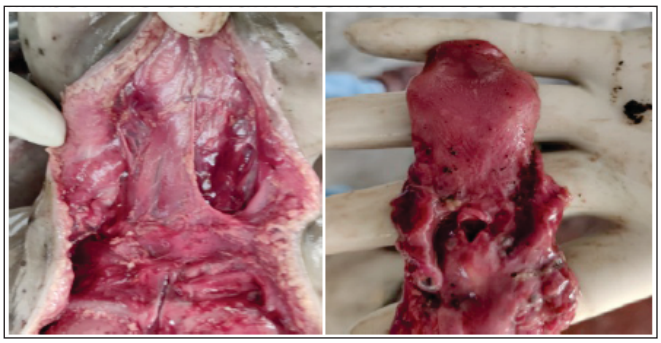

The rest of the findings were unremarkable. Samples were preserved and handed over to the investigating officer for DNA analysis.

Discussion

During an autopsy, doctors establish if the newborn was born alive, stillborn, or dead. In this case, the measurements and the presence of an ossification centre in the sternum indicate that the foetus was full-term when born. Ossification centres, such as those in the lower femur or higher tibia, are important markers of foetal maturity, indicating that the newborn has reached a viable stage of development.8 There was no evidence of maceration, which ruled out intrauterine death. Maceration, which is marked by skin sliding and discolouration, usually occurs when a foetus dies in utero and remains there for a long time.9 The absence of such indications indicates that the neonate did not die before delivery.

No abnormalities were discovered that would make intrauterine life impossible.The existence of inflated lungs with circular borders, a low-lying diaphragm, and a positive hydrostatic test suggested respiration. The hydrostatic test, often known as the "lung float test," involves immersing the lungs in water to determine if they float, indicating that the lungs have been aerated and verifying that the baby breathed after birth.10 The umbilical cord can also reveal information about the birth circumstances. In the event of a hospital delivery, the cord will be cleanly cut and secured. However, if the mother is not ready for delivery, she may not have a sharp instrument to cut the cord. Deliberate attempts to tear the cord with bare hands or pinch with nails result in irregular end margins, as seen in this case.

Mothers are responsible for nearly all occurrences

of neonaticide. 11 A review of forty years of infanticide and neonaticide found that mothers who kill their newborns do so to get rid of an undesired kid or to exact revenge on the child's father.12, 13 The mother's mental disorder may also have a role. According to studies, postpartum psychosis and severe postpartum depression are substantial risk factors for neonaticide.14-16

However, it has been found that mothers who want to live a life free of a newborn may kill their child.17, 18 The patriarchal nature of society, along with the stigma of pregnancy in an unmarried, widowed, or extramarital relationship, can drive a mother to brutally kill and dispose of her kid.19Cultural and societal influences play an important role in such decisions, frequently driving the mother to extreme measures out of anxiety about ostracism and shame. The judicial system punishes women for neonaticide, but the offending malewho impregnated her is rarely investigated or punished. This gap highlights the need for a fairer approach to justice, considering the circumstances surrounding the crime as well as the involvement of all persons involved.20

The current case demonstrates the complex relationship of psychological, cultural, and contextual aspects involved in neonaticide. The significance of a thorough autopsy and extensive forensic examination should be emphasized, as they give vital evidence for understanding the reason and manner of death, ultimately assisting in the pursuit of justice. According to studies, addressing the varied character of such instances requires a multidisciplinary approach that includes forensic pathologists, psychologists, and law enforcement.21 Conclusion The role of circumstantial evidence is crucial in cases of neonaticide. Autopsy findings, combined with thorough investigation and DNA analysis, provide critical evidence in identifying the perpetrator and understanding the circumstances of the crime. The importance of collecting and preserving forensic evidence cannot be overstated, as it plays a pivotal role in achieving justice. This case highlights the need for comprehensive medico-legal investigations and the significance of addressing societal issues that contribute to such tragic events. By understanding the underlying factors and motivations, society can work towards prevention and support measures to reduce the incidence of neonaticide.

REFERENCES

1. Malcomson RD. Forensic Aspects of Perinatal Pathology. Keeling's Fetal and Neonatal Pathology. 2022:891-901.
2. Leal LM, Matos LM. Neonaticidal mothers. InHandbook of Anger, Aggression, and Violence 2023 Aug 25 (pp. 301-311). Cham: Springer International Publishing.
3. Davies A. Filicide Involving Mothers—An Analysis of Case Reviews in England and Scotland 2016–2020. Child Care in Practice. 2024 Jun 5:1-7.
4. Galante N, Blandino A, Disegna M, Franceschetti L, Casali MB. Intentional child and adolescent homicides in Milan (Italy): A 30-year interdisciplinary study. Legal Medicine. 2024 May 1; 68:102433.
5. Leal LM, Matos LM. Neonaticidal mothers. InHandbook of Anger, Aggression, and Violence 2023 Aug 25 (pp. 301-311). Cham: Springer International Publishing. Okanlawon A, Lamade RV, Marques F. Infanticide: By Human Mothers. InEncyclopedia of Sexual Psychology and Behavior 2023 Feb 4 (pp. 1-10). Cham: Springer International Publishing.
6. Okanlawon A, Lamade RV, Marques F. Infanticide: By Human Mothers. InEncyclopedia of Sexual Psychology and Behavior 2023 Feb 4 (pp. 1-10). Cham: Springer International Publishing.
7. Montgomery H. Familiar Violence: A History of Child Abuse. John Wiley & Sons; 2024 Feb7.

8. Perrone S, Caporilli C, Grassi F, Ferrocino M, Biagi E, Dell'Orto V, Beretta V, Petrolini C, Gambini L, Street ME, Dall'Asta A. Prenatal and Neonatal Bone Health: Updated Review on Early Identification of Newborns at High Risk for Osteopenia. Nutrients. 2023 Aug 9;15(16):3515.
9. Joshi A, Sudhir N, Akshunna K. A Compendium on Perinatal Autopsy in Neonats. Cureus. 2023;15(1).
10. Lupariello F, Mirri F, Genova T, Mussano F, Botta G, DI VELLA G. A Pilot Study to Investigate If and How Postmortem Micro-Computed Tomography (Micro-CT) Can Be Used to Differentiate Stillbirths from Livebirths. InProceedings of the 75th Anniversary Conference 2023 (Vol. 29, No. I96, pp. 752-752). The American Academy of Forensic Sciences.
11. Leal LM, Matos LM. Neonaticidal mothers. InHandbook of Anger, Aggression, and Violence 2023 Aug 25 (pp. 301-311). Cham: Springer International Publishing.
12. Atreya A, Gyawali L, Devkota I, Pathak B. Medicolegal Evaluation of an Abandoned Dead Neonate: A Case Report. JNMA J Nepal Med Assoc. 2021;59(235):292-294. Published 2021 Mar 31.
13. Moen M, Bezuidenhout C. Killing your children to hurt your partner: A South African perspective on the motivations for revenge filicide. Journal of Investigative Psychology and Offender Profiling. 2023 Jan;20(1):33-47.
14. Jansen van Rensburg N, Spies R, Malan L. Infanticide and its relationship with postpartum psychosis: a critical interpretive synthesis. Journal of criminal psychology. 2020 Nov 30;10(4):293-310.
15. Kingston A. Role of Perinatal Psychiatric Complications in Infanticide and Filicide. Infanticide and Filicide: Foundations in Maternal Mental Health Forensics. 2020 Dec 9;111.
16. Milia G, Noonan M. Experiences and perspectives of women who have committed neonaticide, infanticide and filicide: A systematic review and qualitative evidence synthesis. Journal of Psychiatric and Mental Health Nursing. 2022 Dec;29(6):813-28.
17. Timmermann J. The Quandary of Infanticide in Kant's 'Doctrine of Right'. Archiv für Geschichte der Philosophie. 2024 Jun 6;106(2):267-94.
18. Milne E. Putting the fetus first-legal regulation, motherhood, and pregnancy. Mich. J. Gender &L.. 2020; 27:149.
19. Kuriachan AM. The Tragedy of Female Infanticides with Reference to the Books' Disappearing Daughters by Gita Aravamudan and 'Witness the Night' by Kishwar Desai. Issue 1 Indian JL & Legal Rsch.. 2022; 4:1.
20. Geldenhuys K. The ultimate spitefulness murdering a partner's children. Servamus Community-based Safety and Security Magazine. 2024 May 1;117(5):16-20.
21. Baldino G, Mondello C, Sapienza D, Stassi C, Asmundo A, Gualniera P, Vanin S, Ventura Spagnolo E. Multidisciplinary Forensic Approach in "Complex" Bodies: Systematic Review and Procedural Proposal. Diagnostics. 2023; 13(2):310